Novel methods of prognostication

MRI - diffusion tensor imaging

Lionel Velly

MD, PhD
Neuroanesthesiologist and intensivist
Marseille, France

Brain imaging and pronostication after OHCA

Neurological prognostication of outcome in patients in coma after cardiac arrest

Andrea O Rossetti, Alejandro A Rabinstein, Mauro Oddo

CARDIAC ARREST

Review



Personal View

Disorders of consciousness: responding to requests for novel diagnostic and therapeutic interventions

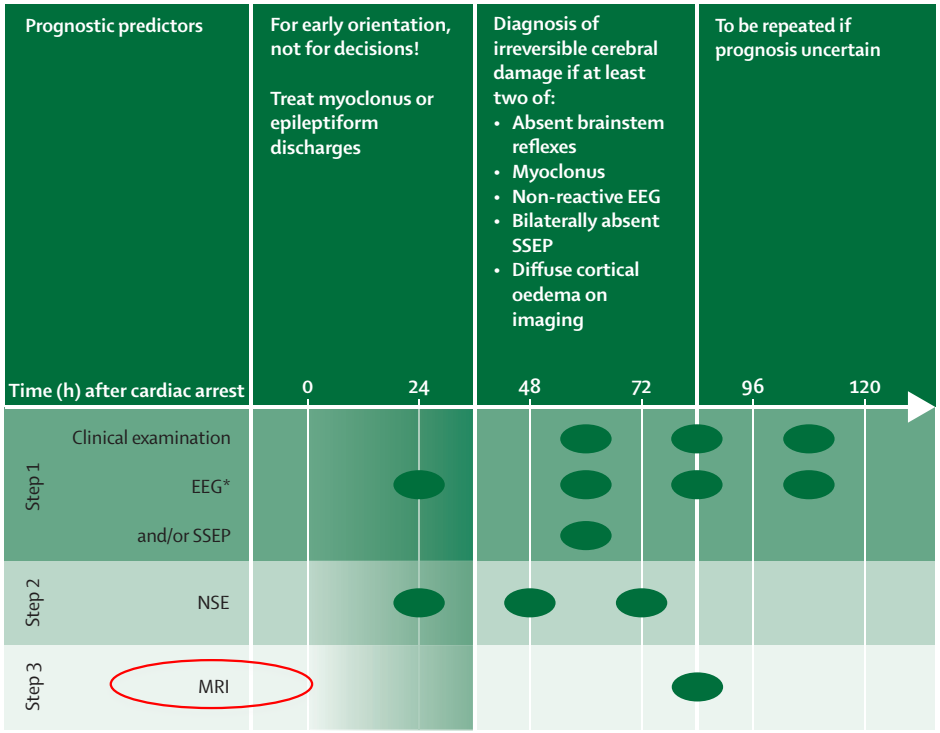

Targeted temperature management and sedation

Lancet Neurol 2016

QUALITATIVE MRI

T2

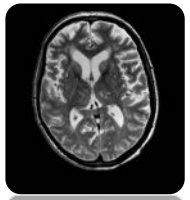

3D-T1
IR-FSPGR (GE)
MPR (Siemens / Philips)

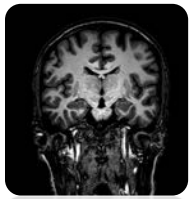

T2* or SWI

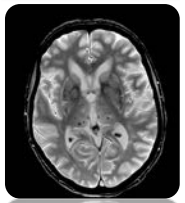

T2 FLAIR (3 mm)

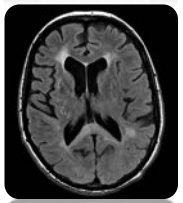

Conventional MRI

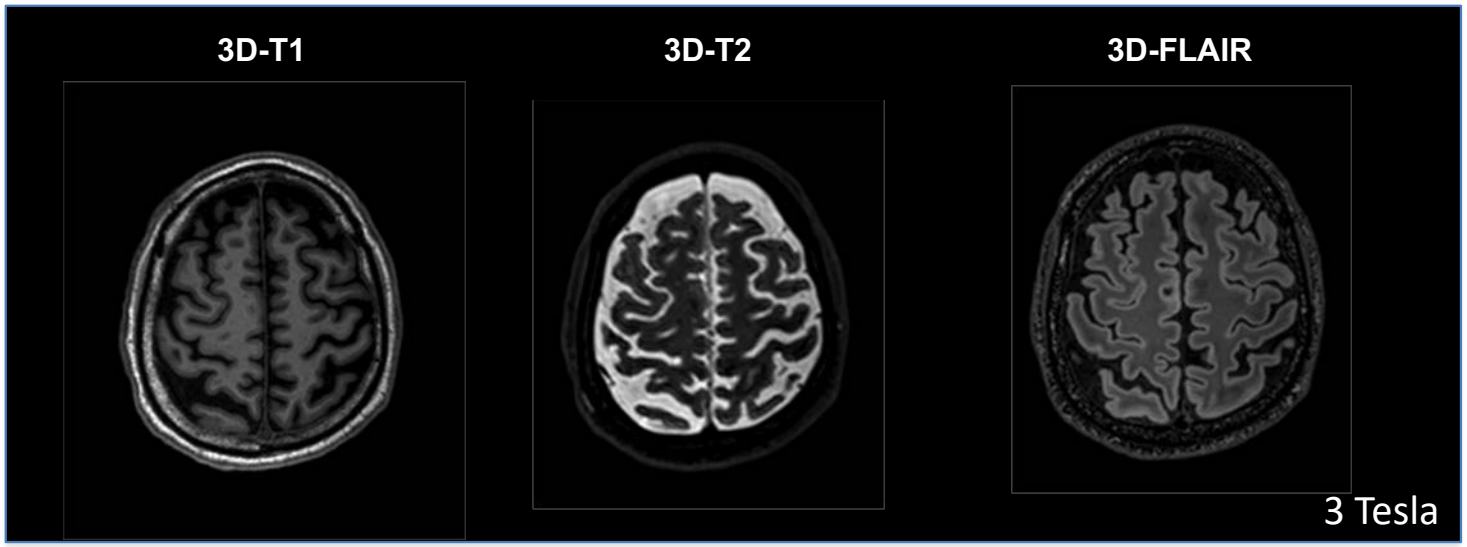

all in 3D resolution : 1 mm

MRI FLAIR hyper intensity signal in good outcome

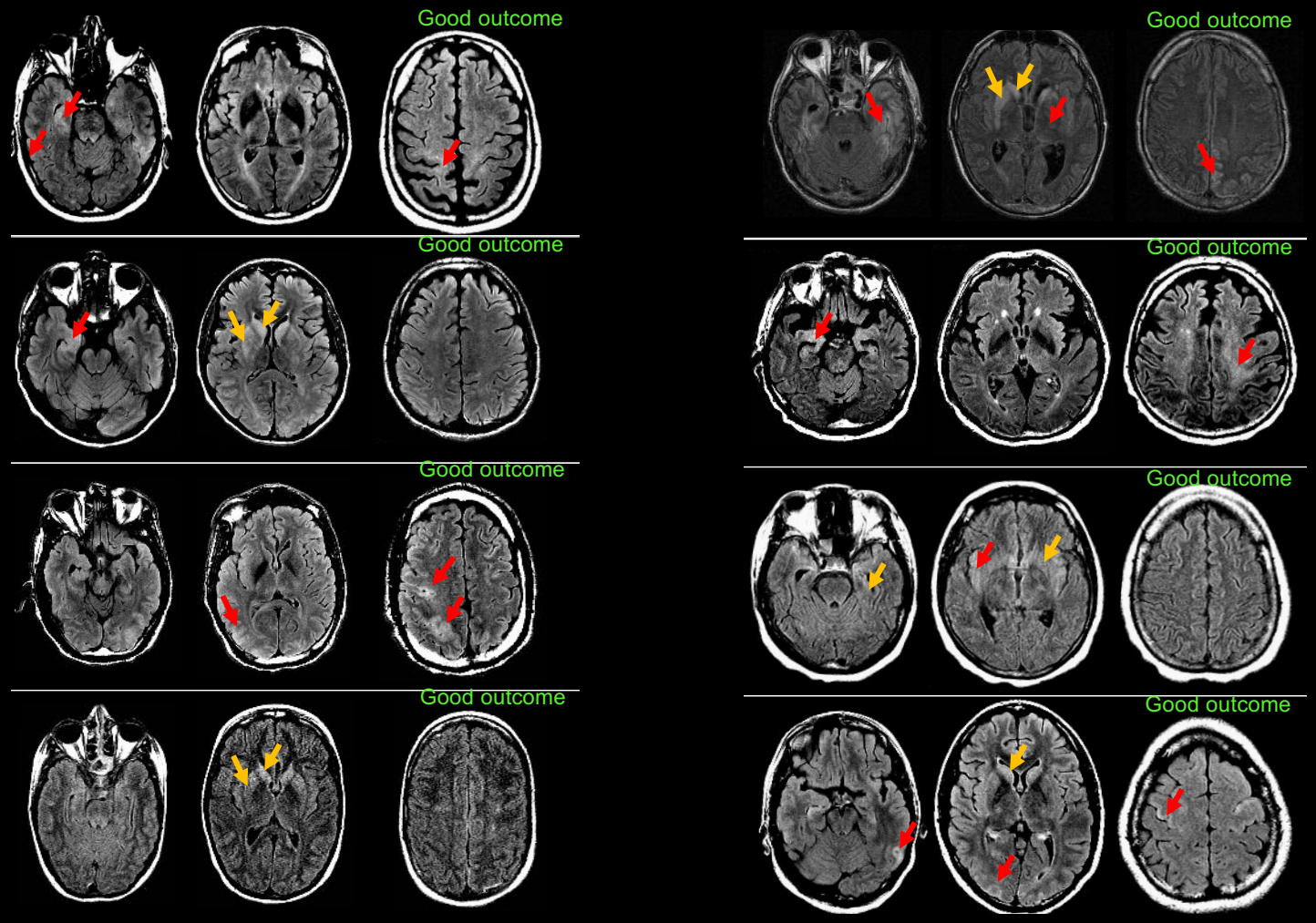

Velly et al., Lancet Neurol 2018

Improvement of MRI

Quantitative MRI

3D-T1
IR-FSPGR (GE)
MPR (Siemens / Philips)

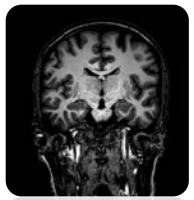

T2 (2mm)

T2* or SWI

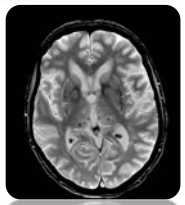

T2 FLAIR (3 mm)

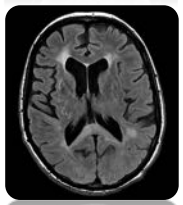

Structural

DWI
(ADC)

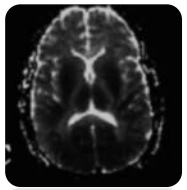

DTI

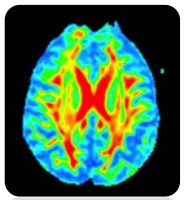

FA

Metabolic

SVS pons

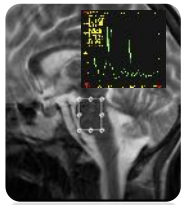

CSI basal ganglia

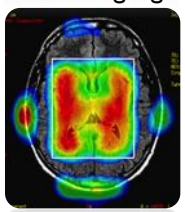

Functional

fMRI BOLD
(resting State)

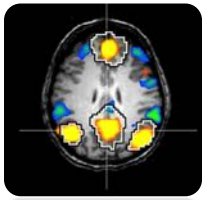

QUANTITATIVE MRI

Diffusion weighted MRI

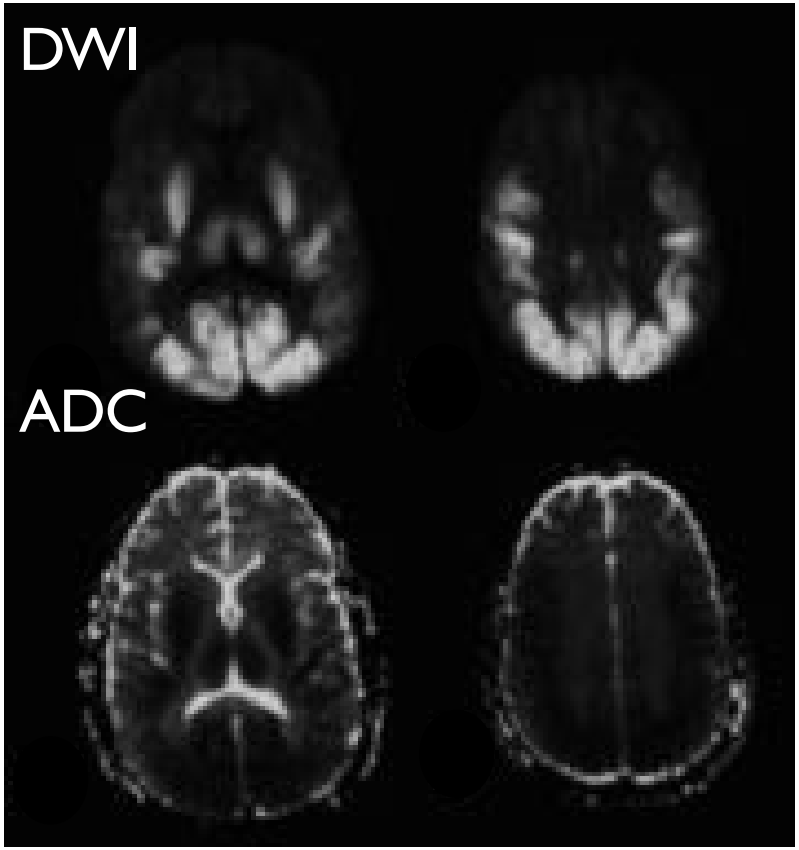

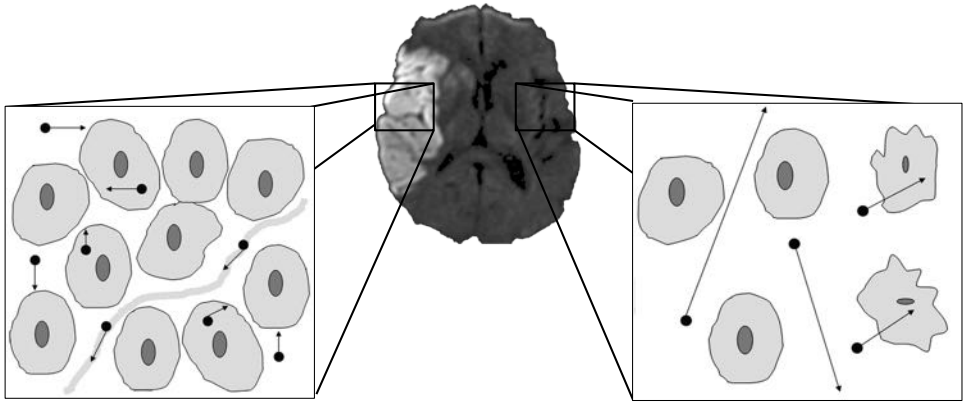

ADC and cardiac arrest

Prognostic Value of Brain Diffusion-Weighted Imaging after Cardiac Arrest

Christine A. C. Wijman, MD, PhD,[1] Michael Mlynash, MD, MS,[1] Anna Finley Caulfield, MD,[1] Amie W. Hsia, MD,[1,2] Irina Eyngorn, MD,[1] Roland Bammer, PhD,[3,4] Nancy Fischbein, MD,[4] Gregory W. Albers, MD,[1] and Michael Moseley, PhD[3,4]

CPC 1

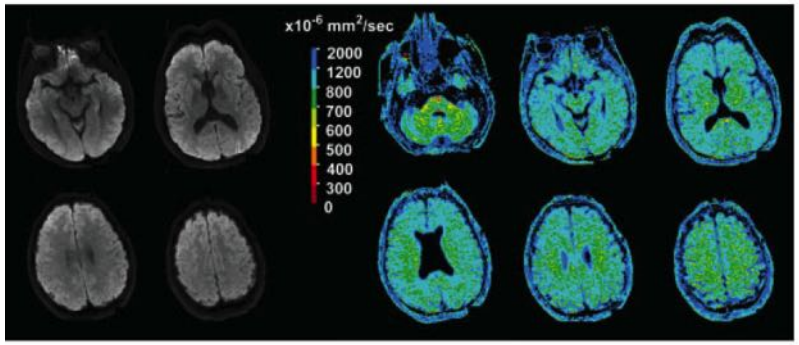

CPC 5

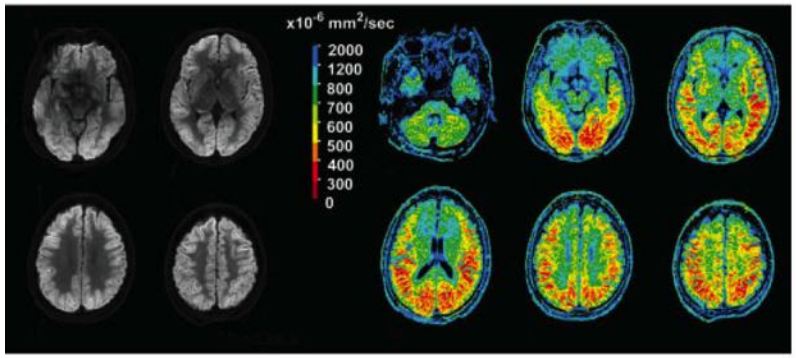

% brain with ADC<450x10^{-6} mm^3/sec

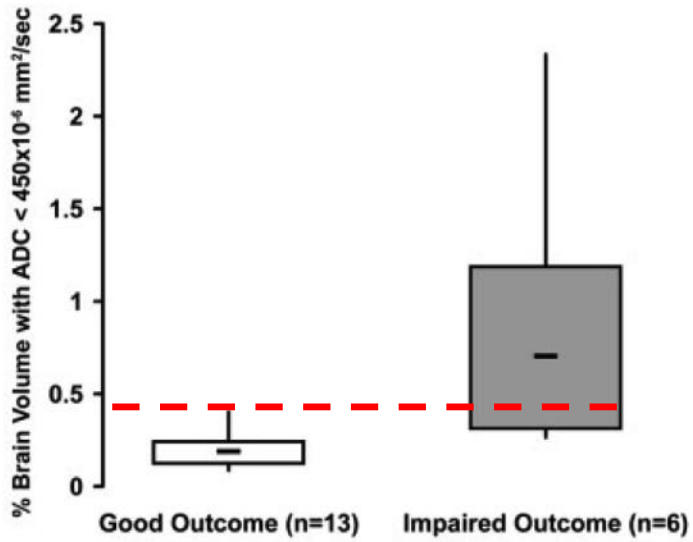

Test Type	Poor Outcome (n)	FP	FN	TP	TN	Sensitivity	Specificity	PPV	NPV
Neurological examination	21	0	12	9	11	43%	100%	100%	48%
MRI	21	0	4	17	11	81%	100%	100%	73%

FP = number of patients with a false-positive test result; FN = number of patients with a false-negative test result; TP = number of patients with a true positive test result; TN = number of patients with a true negative test result; PPV = positive predictive value; NPV = negative predictive value. MRI = Magnetic Resonance Imaging.

ADC and cardiac arrest

Prognostic Value of Brain Diffusion-Weighted Imaging after Cardiac Arrest

Christine A. C. Wijman, MD, PhD,[1] Michael Mlynash, MD, MS,[1] Anna Finley Caulfield, MD,[1] Amie W. Hsia, MD,[1,2] Irina Eyngorn, MD,[1] Roland Bammer, PhD,[3,4] Nancy Fischbein, MD,[4] Gregory W. Albers, MD,[1] and Michael Moseley, PhD[3,4]

CPC 1

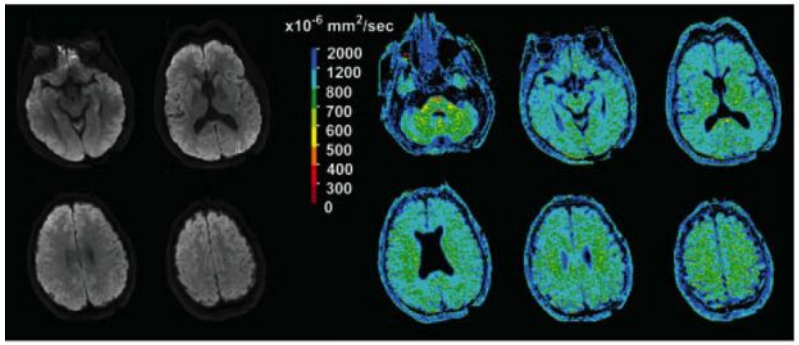

CPC 5

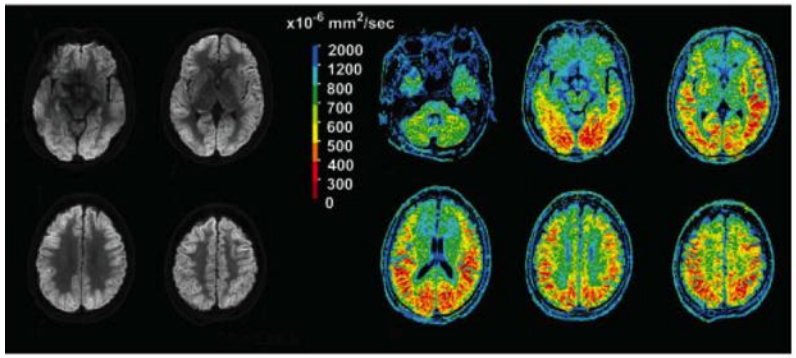

very TRANSIENT

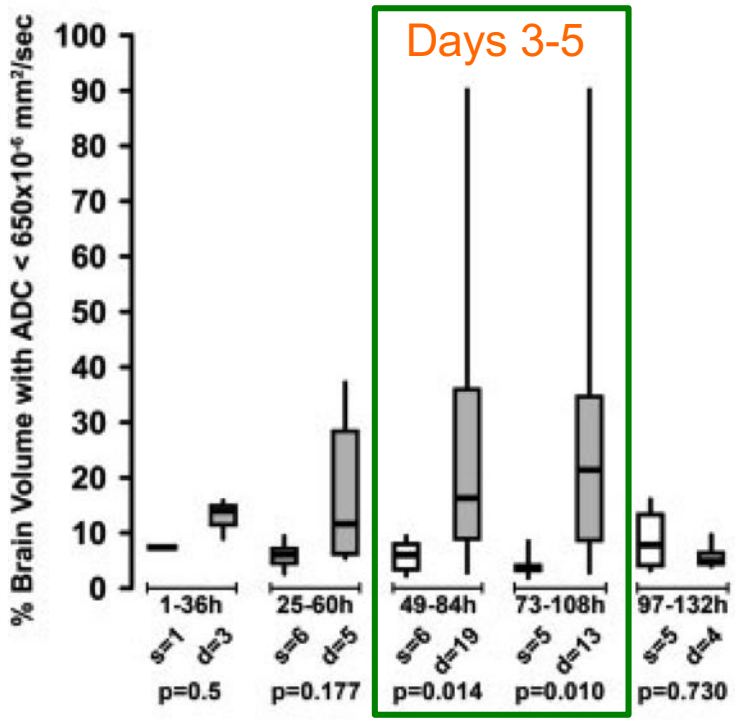


URGENCE
TECHNIQUE

ADC and cardiac arrest

Multi-Center Study of Diffusion-Weighted Imaging in Coma After Cardiac Arrest

K. G. Hirsch[1] · M. Mlynash[1] · I. Eyngorn[1] · R. Pirsaheli[1] · A. Okada[2] · S. Komshian[1] · C. Chen[3] · S. A. Mayer[4] · J. F. Meschia[5] · R. A. Bernstein[6] · O. Wu[7] · D. M. Greer[8] · C. A. Wijman[1] · G. W. Albers[1]

Diffusion weighted MRI

DWI between D2-D6 post-arrest

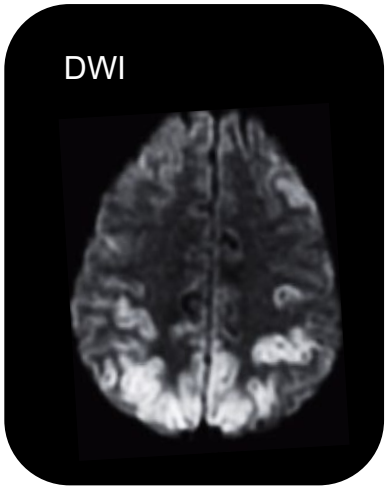

Brain volume % at ADC <650 x10^{-6} mm^2 /s to predict poor outcome

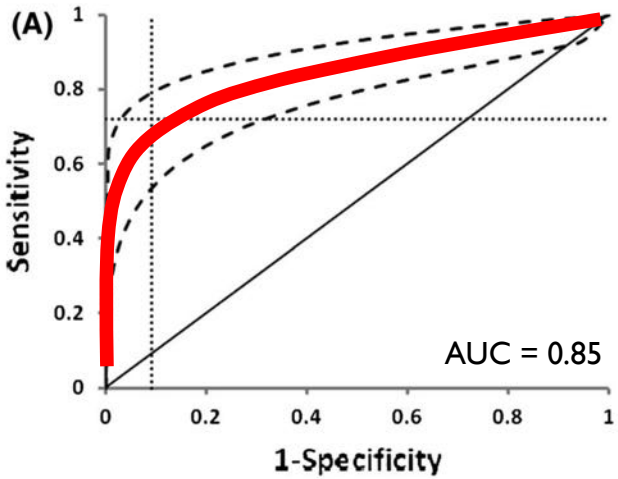

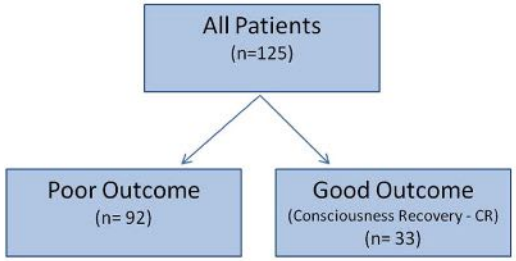

Se 40% Sp 100%

Hirsch et al Neurocrit Care. (2016);24:82-9

Diffusion Tensor Imaging

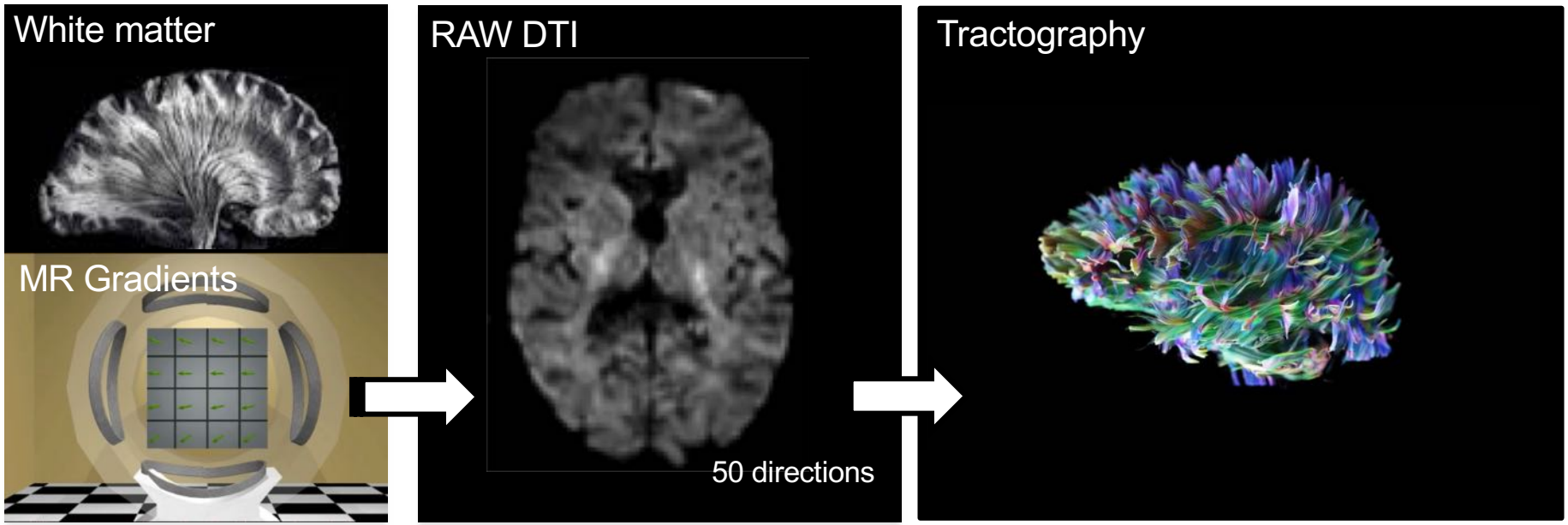

Quantitative DTI

Diffusion Tensor Imaging

MD (aDC)
(mean diffusivity)

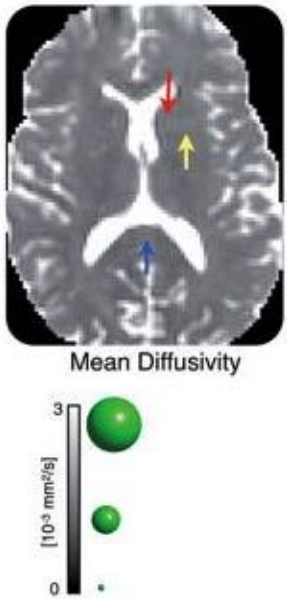

FA
(fractional anisotropy)

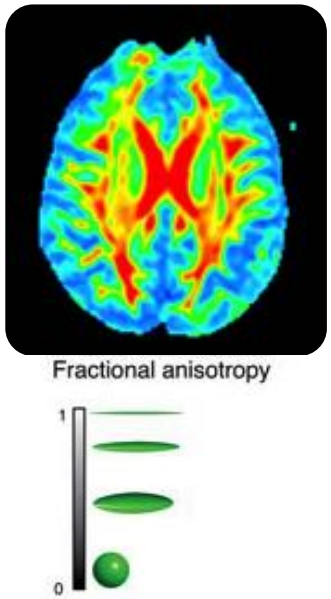

Quantitative DTI

Fractional Anisotropy (FA)

Low FA
(isotropic)

High FA
(anisotropic)

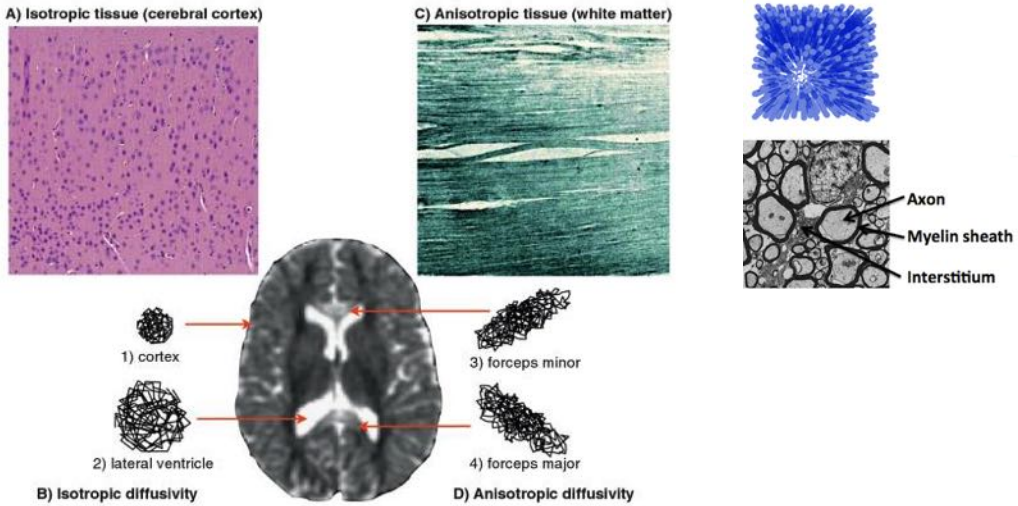

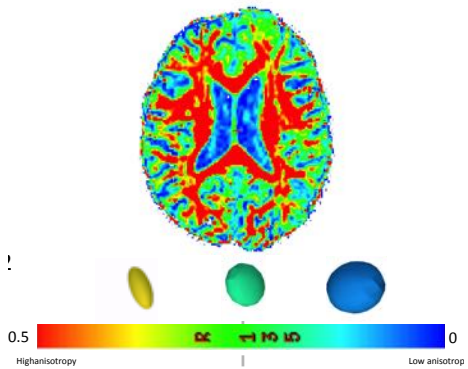

Quantitative DTI

Fractional Anisotropy (FA)

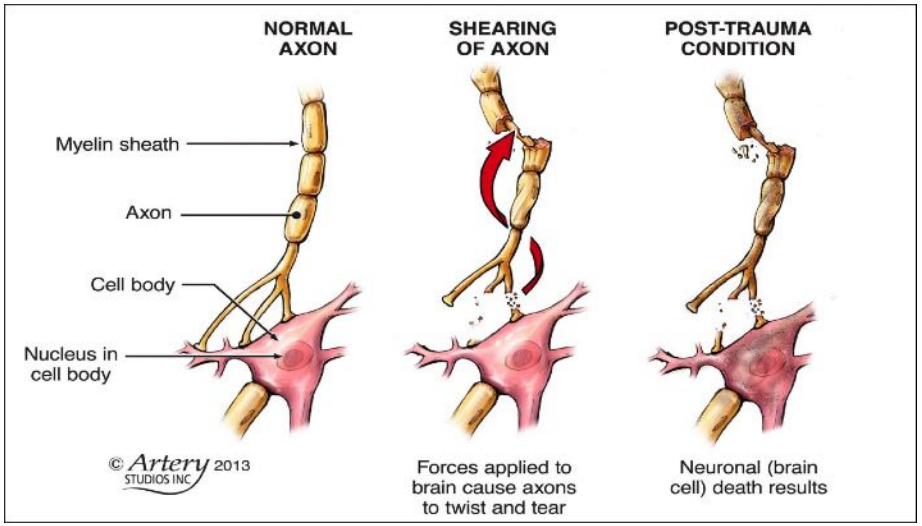

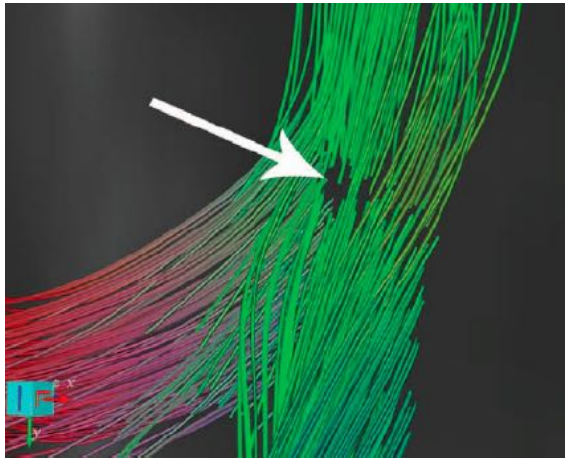

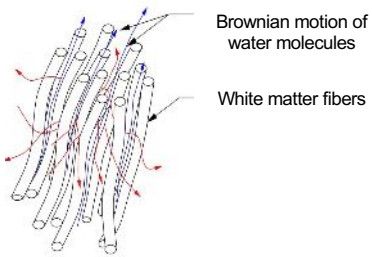

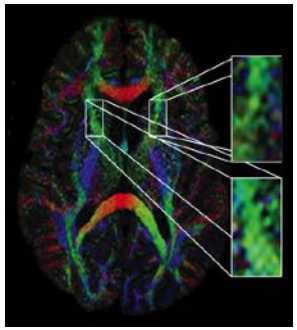

Quantitative DTI

Fractional Anisotropy (FA)

Cardiac Arrest

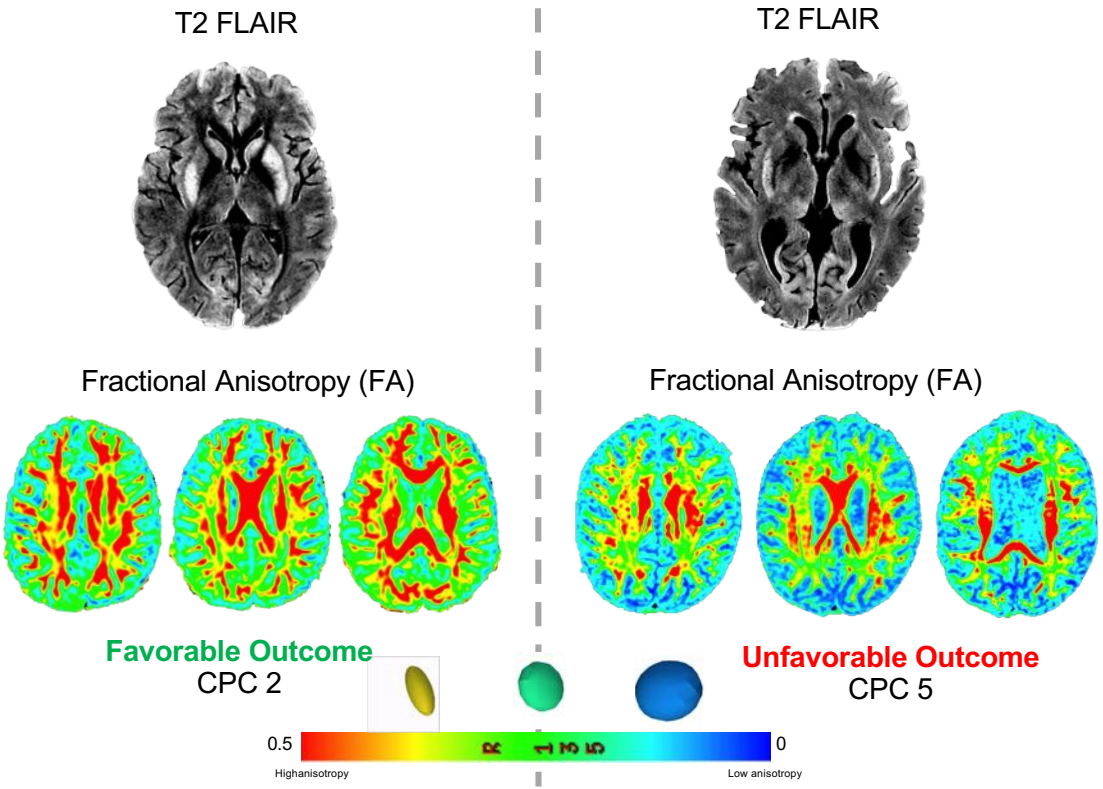

WM degeneration after cardiopulmonary arrest

Quantitative DTI

Quantitative DTI

FA measurement

3DT1

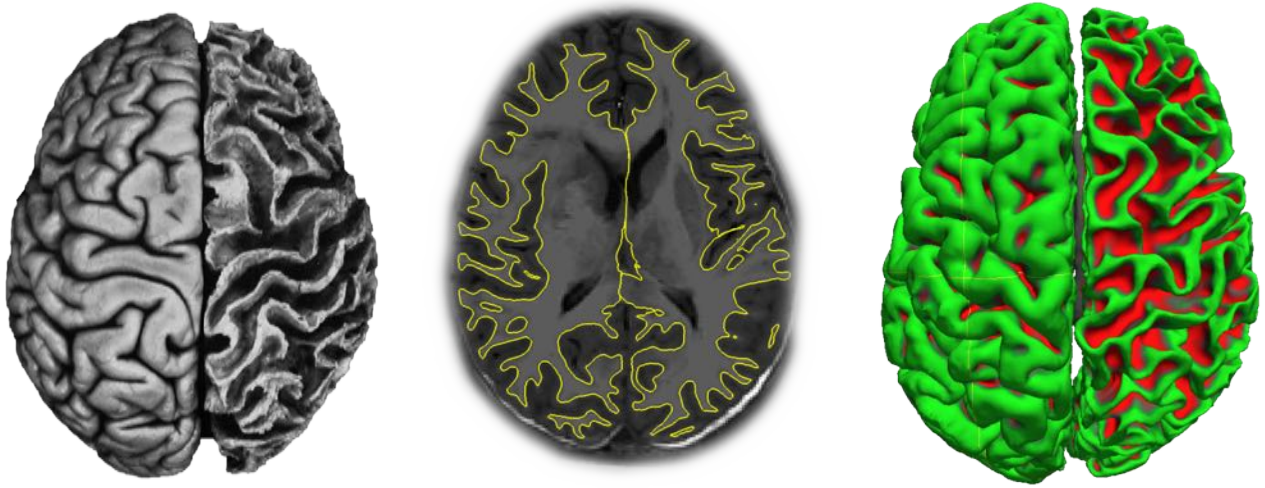

MRI white matter segmentation

Quantitative DTI

Quantitative DTI

FA measurement

3DT1 + FA map

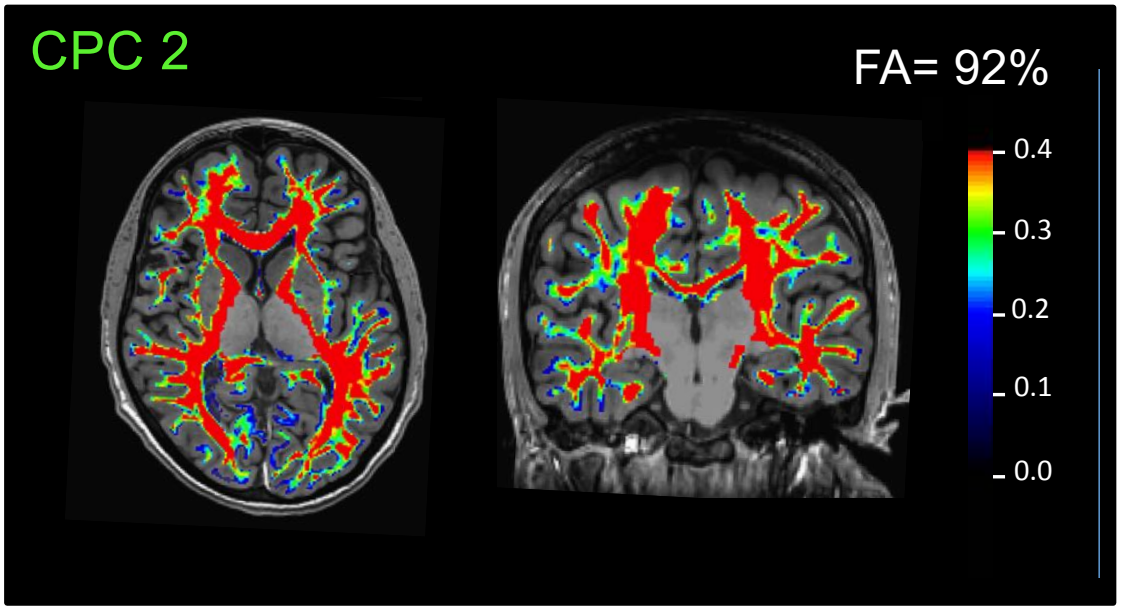

White Matter FA = **92%**

of controls

Quantitative DTI

Quantitative DTI

FA measurement

3DT1 + FA map

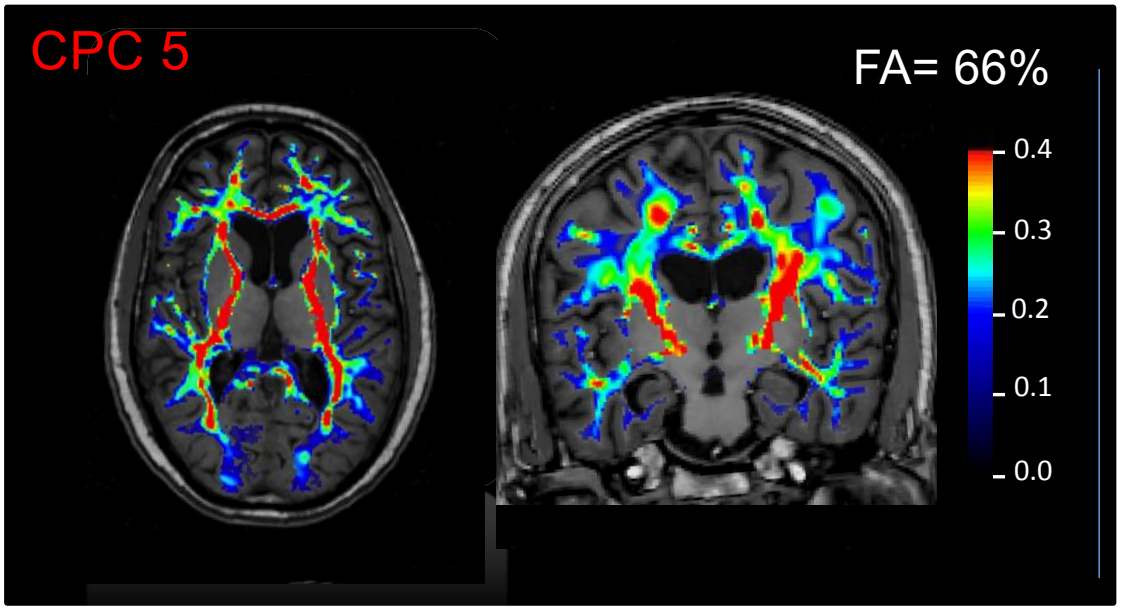

White Matter FA = **66%**

of controls

Quantitative DTI

There is a need for a **normalization procedure**

Metrics (FA, MD, L1 and Lt) depend on :

- *Manufacturers*
- *Magnetic field*
- *Number of directions*
- *Antenna*
- *Slice thickness*
- *Spacial resolution*
- *TE*
- *Faraday cage*

Normal values must be assessed in controls

Normalization process : Nb of controls needed

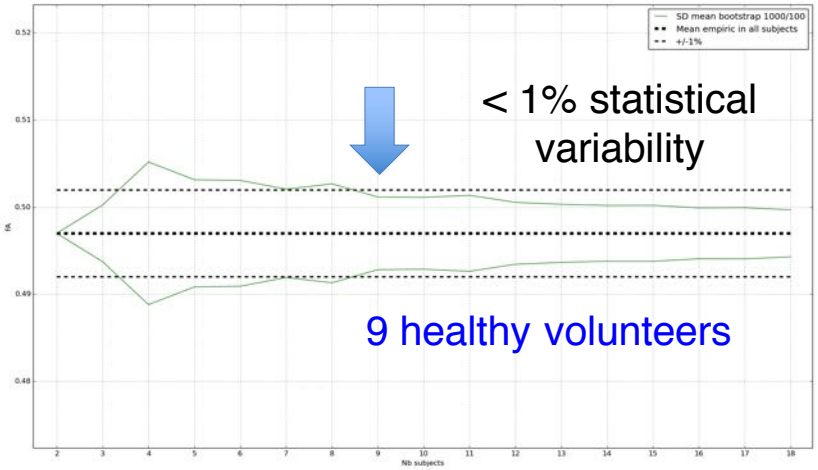

THE LANCET
Neurology

Use of Brain Diffusion Tensor Imaging for the Prediction of Long-Term Outcome in Patients after Cardiac Arrest: a multicentre, prospective, cohort study

Lionel Velly, Vincent Perlbarg, Thomas Boulier, Nicolas Adam, Sebastien Delphine, Charles-Edouard Luyt, Valentine Battisti, Gregory Torkomian, Charlotte Arbelot, Russell Chabanne, Betty Jean, Carol Di Perri, Steven Laureys, Giuseppe Citerio, Alessia Vargiolu, Benjamin Rohaut, Nicolas Bruder, Nadine Girard, Stein Silva, Vincent Cottenceau, Thomas Tourdias, Olivier Coulon, Bruno Riou, Lionel Naccache, Rajiv Gupta, Habib Benali, Damien Galanaud, Louis Puybasset, for the MRI-COMA Investigators*

MRI-COMA

16 centers in France, Italy, and Belgium

200 OHCA

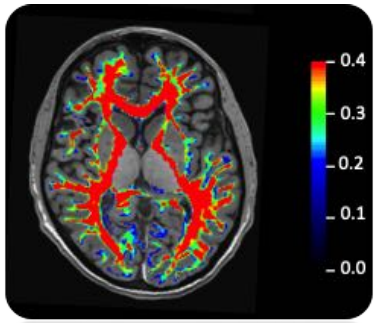

Velly et al., Lancet Neurol 2018

MRI-COMA STUDY

Prospective, observational cohort study

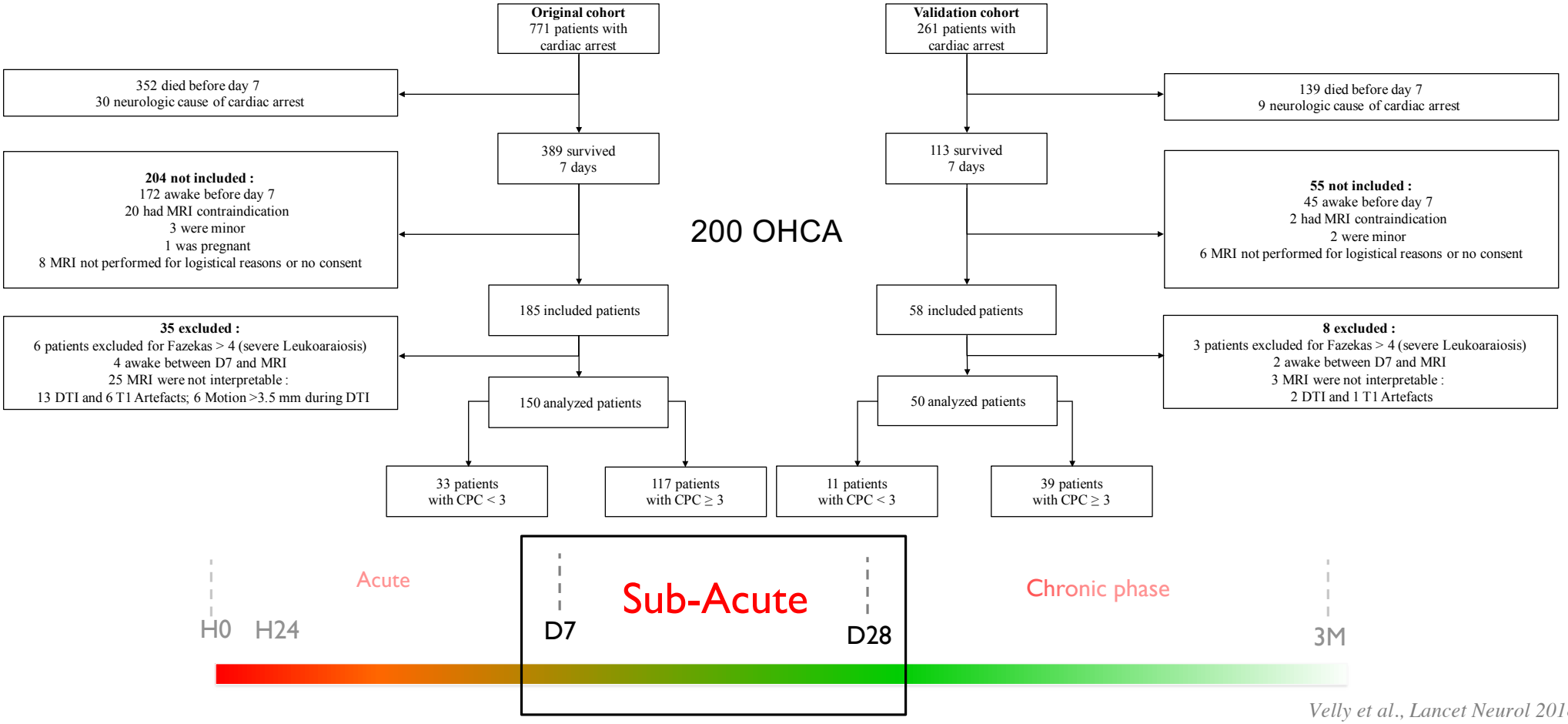

Velly et al., Lancet Neurol 2018

MRI-COMA STUDY

Individual MD and FA of the 150 OHCA

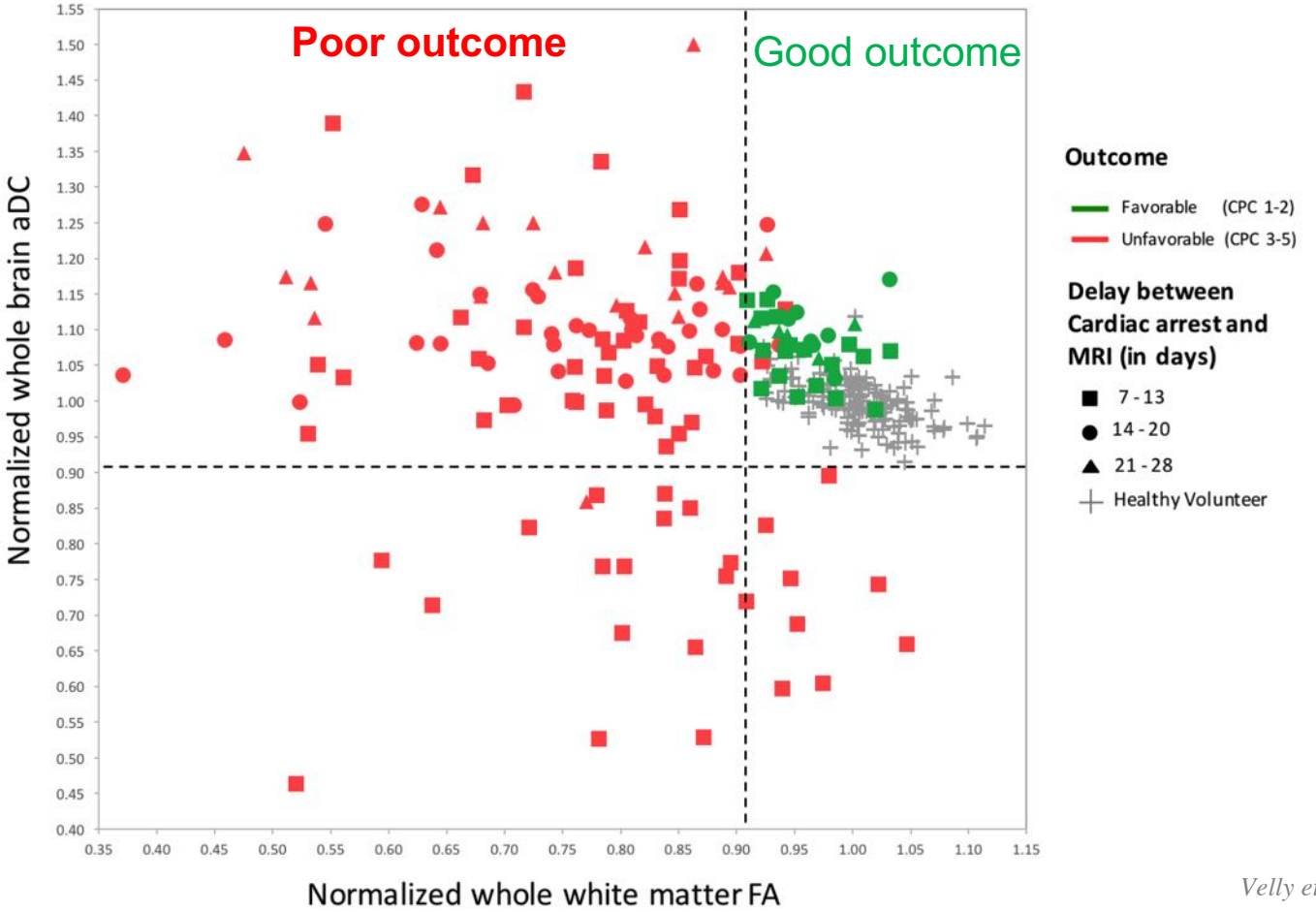

Velly et al., Lancet Neurol 2018

MRI-COMA STUDY

ROC curves

FA
Sensitivity 92 %
Specificity 100 %

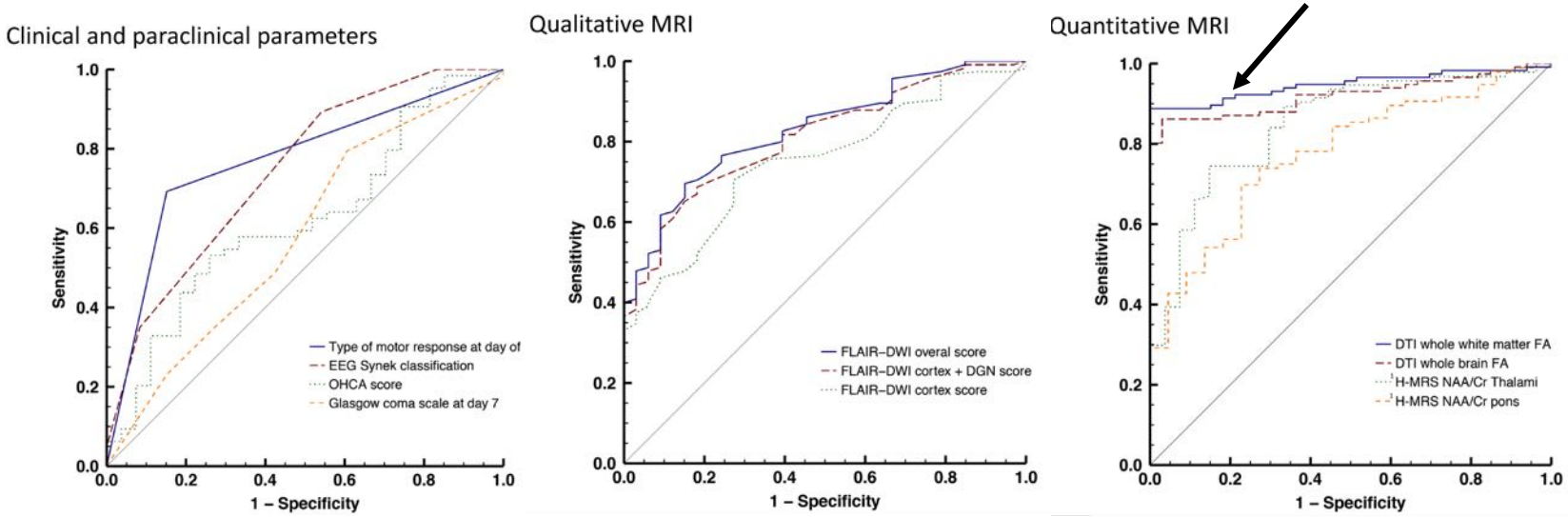

Velly et al., Lancet Neurol 2018

Clinical case 2

Clinical case of M. C, **68 years old**, ICU admission after **cardiac arrest**.
coma*Web* expertise for possible care withdrawal at D14.

Raw Fa and MD values

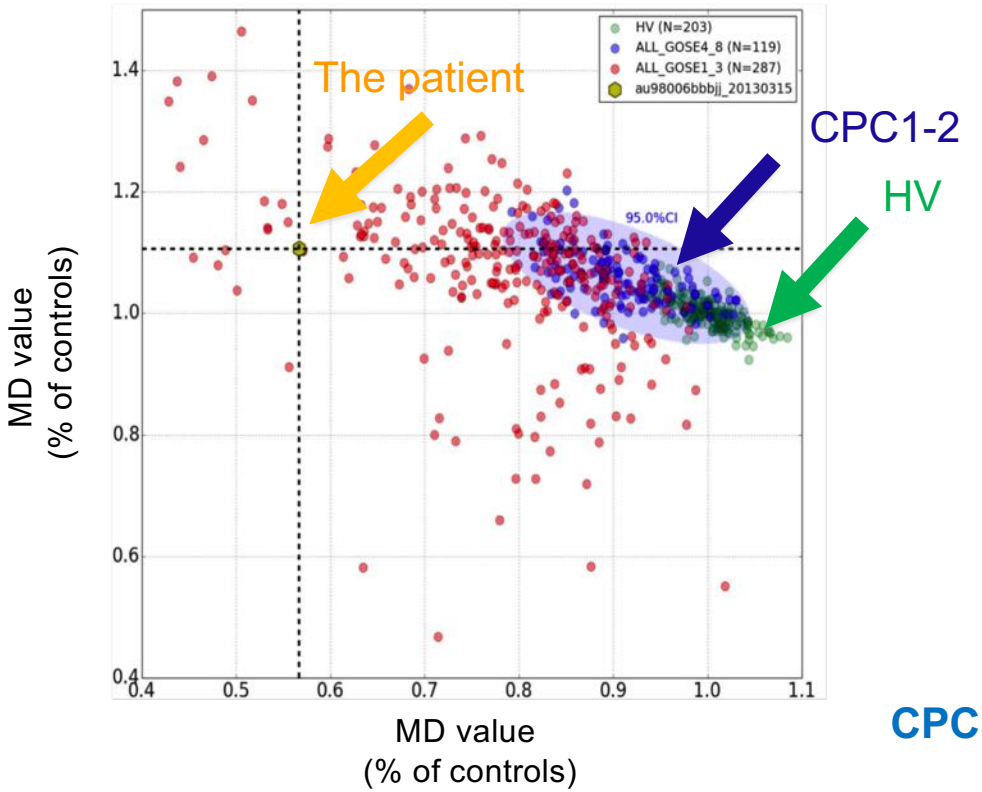

The patient : 100% probability of bad outcome

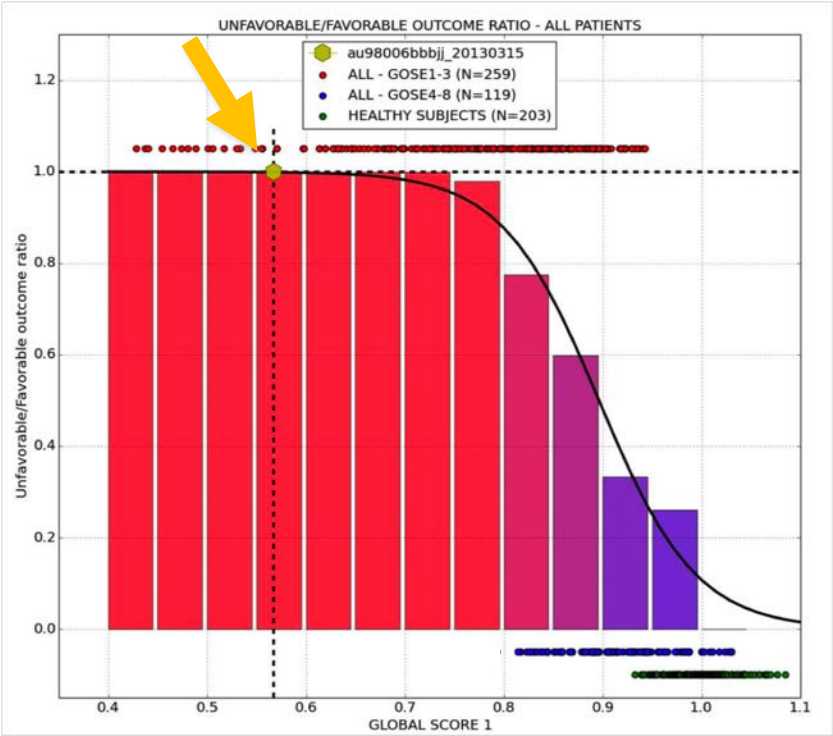

CPC5 at 1 year

coma*Web*

Grey Zone …

Take home message

CT scan is unreliable

FLAIR lesions are unspecific except for diffuse hyper intensity signal in the cortex

DWI can be easily replace by DTI

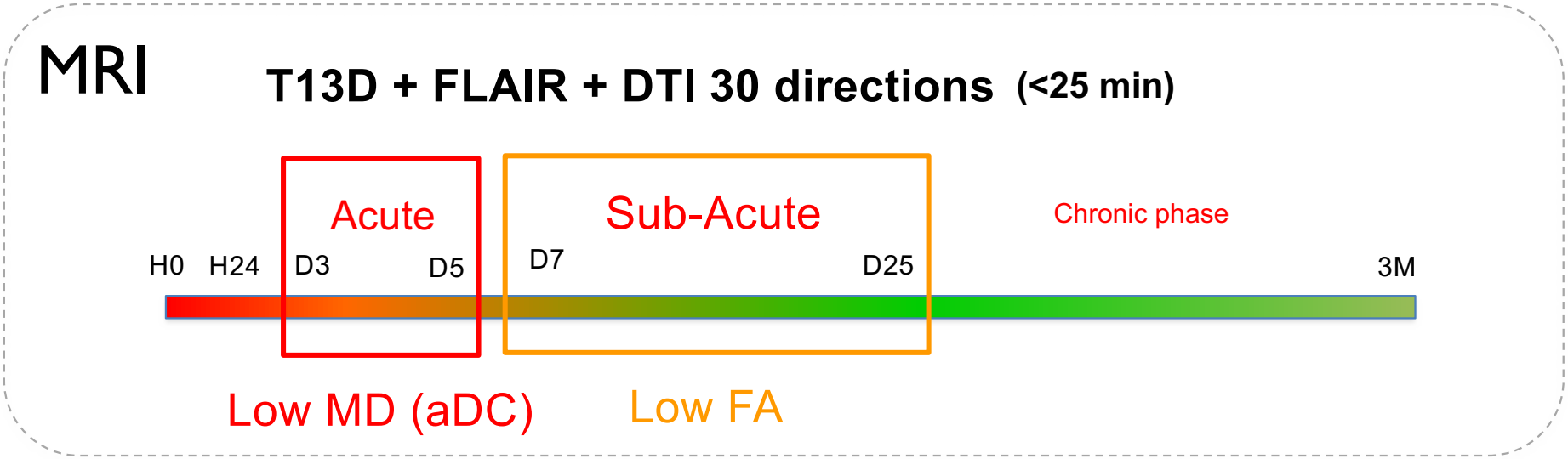

Sensitivity 40% 90% for 100% specificity

Take home message

MRI CONTRAINDICATIONS

Heart pacemaker

Metallic foreign body (metal sliver) in eye

Aneurysm clip > 20 years

ARDS

Intracranial hypertension